*Journal of*
*Scientific Advances in Dentistry*

REVO PUBLICATION

*Case Report*

# Surgical management of large periapical lesion in maxillary anterior teeth: A case report

**Manasi Surwade[1*], Anuradha Patil[1], Sumanthini M. V[1], Divya Naik[1]**

[1]Department of Conservative Dentistry and Endodontics, MGM Dental College and Hospital, Navi Mumbai, Maharashtra, India

## Abstract

**Background:** Periapical lesions arise from pulpal necrosis and microbial infection. While most heal with conventional root canal treatment, large cyst-like lesions may require surgical intervention. Trauma is a common cause of pulpal necrosis in anterior teeth, particularly in young patients. Cone beam computed tomography (CBCT) helps assess lesion size, cortical involvement, and proximity to vital structures, improving treatment planning and prognosis.

**Aim:** The aim of this case report is to present the surgical management of a large periapical lesion associated with maxillary anterior teeth using a combined nonsurgical endodontic and periapical surgical approach.

**Case Description:** A 17-year-old female presented with pain and mild swelling in the maxillary anterior region, with a history of trauma three years earlier. Clinical and radiographic examinations revealed non-vital teeth 21 and 22 and a well-defined periapical radiolucency (26 × 44 × 18 mm) extending toward tooth 23. Root canal treatment was performed for teeth 21, 22, and 23, followed by surgical enucleation, apicoectomy of teeth 21 and 22, and retrograde filling with mineral trioxide aggregate. Histopathology confirmed periapical granuloma with precystic changes. Six-month follow-up showed progressive bone regeneration and symptom resolution.

**Conclusion:** Combined nonsurgical and surgical management can effectively treat large periapical lesions in the anterior maxilla, resulting in predictable healing and favourable clinical outcomes.

Clinical Significance: CBCT-guided diagnosis, complete cyst enucleation, apicoectomy, and use of bioactive retrograde materials play a crucial role in successful management of large periapical lesions.

**Keywords:** Periapical lesion, Apicoectomy, Surgical endodontics, CBCT, Mineral trioxide aggregate.

**Received:** 22-08-2026

**Accepted:** 18-10-2026

**Published:** 21-11-2026

***Corresponding author:** Manasi Surwade
Email: manasisurwade14@gmail.com

https://doi.org/10.65929/JSAD.2026.1.3.007

**How to cite this article:** Surwade M, Patil A, Sumanthini MV, Naik D. Surgical management of large periapical lesion in maxillary anterior teeth: A case report. *J Sci Adv Dent.* 2026;1(3):123-130.

© 2026 The Author(s). Published by REVO Publication.

This is an Open Access article distributed under the terms of the Creative Commons Attribution 4.0 International License (CC BY 4.0) (https://creativecommons.org/licenses/by/4.0/), which permits unrestricted use, distribution, and reproduction in any medium, provided the original work is properly cited.

## 1. Introduction

Periapical pathoses arise as a biological response of periradicular tissues to microbial colonization within the necrotic pulp space. These inflammatory lesions may manifest as granulomas, abscesses, or radicular cysts, with the latter being the most prevalent cystic lesion of odontogenic inflammatory origin.[1] Traumatic injuries frequently contribute to pulpal necrosis in maxillary anterior teeth because of their vulnerable position in the dental arch.[2]

Conventional orthograde root canal therapy remains the primary modality for management of periapical lesions, as effective disinfection of the root canal system facilitates periapical repair.[3] However, lesions of larger dimensions demonstrating radiographic cortication and cyst-like characteristics may show incomplete healing following nonsurgical therapy alone, thereby necessitating surgical intervention.[4]

Advances in three-dimensional imaging such as cone beam computed tomography have significantly improved diagnostic precision by enabling detailed evaluation of lesion size, cortical bone involvement, and anatomical relationships.[5] Surgical procedures including lesion enucleation combined with apicoectomy provide direct access for removal of pathological tissues, reduction of microbial load, and histopathological confirmation of the diagnosis.

## 2. Case Description

A 17-year-old female patient reported with pain and mild swelling in the maxillary anterior region for ten days. The patient had a history of dental trauma approximately three years prior. Clinical examination revealed labial cortical plate expansion and tenderness on percussion in relation to teeth 21 and 22. Tooth 23 was asymptomatic. No sinus tract or mobility was observed. Pulp vitality testing revealed non-vital responses in teeth 21 and 22, whereas tooth 23 responded positively.

Intraoral periapical radiography demonstrated a well-defined radiolucency involving the apical regions of teeth 21 and 22 extending toward tooth 23. CBCT examination revealed a corticated radiolucent lesion with mesiodistal dimension measuring 26*44*18 mm approximately with thinning and mild expansion of the buccal cortical plate. Based on clinical and radiographic findings, a provisional diagnosis of radicular cyst was established.

Root canal therapy was performed under rubber dam isolation. Working length was determined using an electronic apex locator and confirmed radiographically. Cleaning and shaping were performed using rotary nickel-titanium instruments with irrigation using 3% sodium hypochlorite. Calcium hydroxide intracanal medicament was placed for two weeks. At the subsequent visit, obturation was completed using gutta-percha and Ah Plus resin sealer with lateral compaction technique. Intentional root canal treatment was performed for tooth 23 considering surgical accessibility and radiographic involvement.

Periapical surgery was performed after one week. A trapezoidal full-thickness mucoperiosteal flap extending from tooth 21 to tooth 24 was reflected. A bony window was created to access the lesion, which was enucleated in toto followed by curettage of the periapical region. Apical resection of approximately 3 mm was carried out for teeth 21 and 22. Retrograde cavities were prepared and filled with mineral trioxide aggregate due to its superior sealing ability and bioactivity.[7] The surgical site was irrigated and sutured. Histopathological examination confirmed periapical granuloma with precystic changes, characterized by chronic inflammatory infiltrate.

Postoperative healing was uneventful. Follow-up radiographs demonstrated reduction in lesion size at three months, trabecular bone formation and significant bone regeneration at six months.

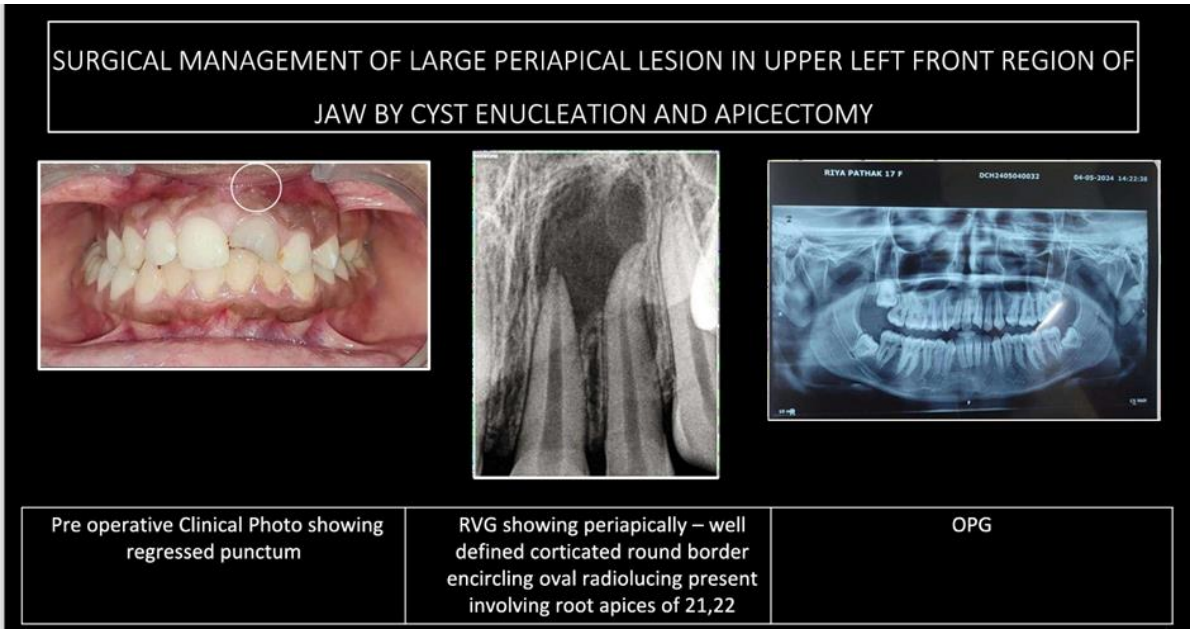


**Figure 1:** Pre-operative intra-oral clinical photograph showing discoloration and regressed sinus tract (punctum) in relation to maxillary left anterior teeth region

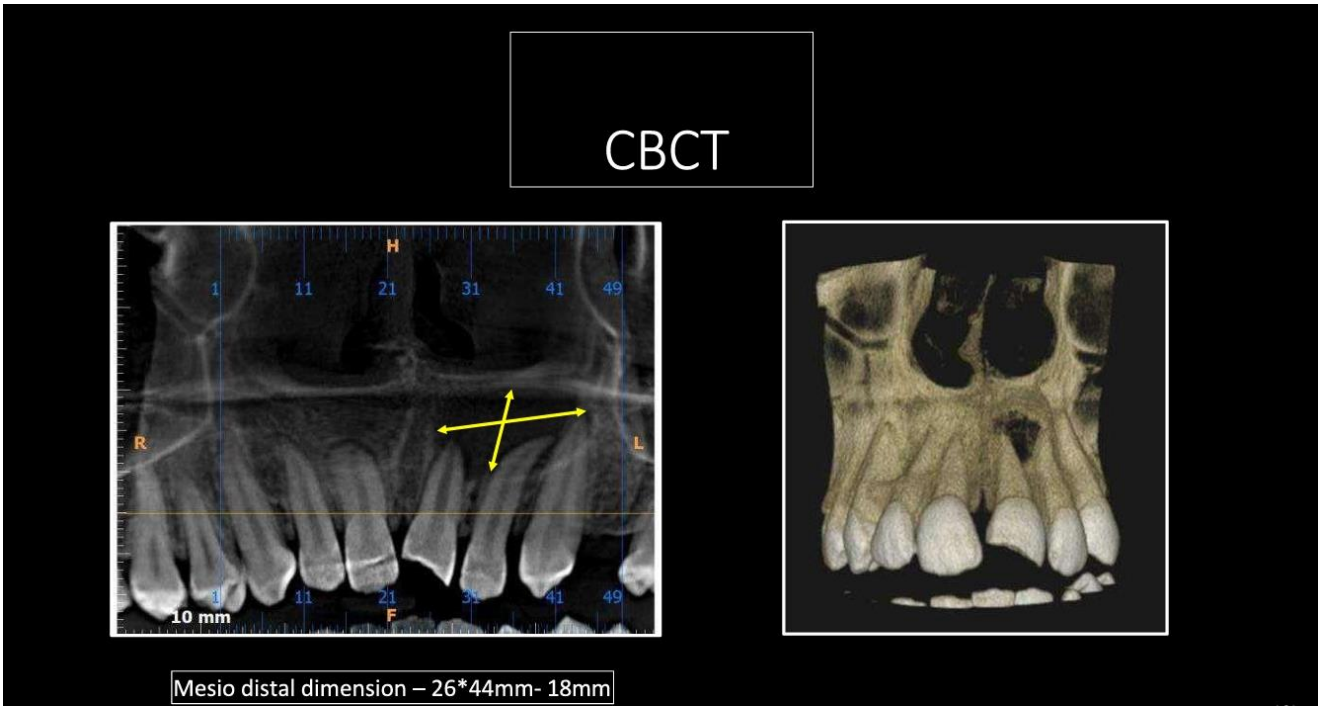


**Figure 2:** Pre-operative intraoral periapical radiograph (IOPA) and orthopantomogram (OPG) showing a well-defined corticated oval radiolucency involving the apical region of teeth 21 and 22 suggestive of a large periapical lesion

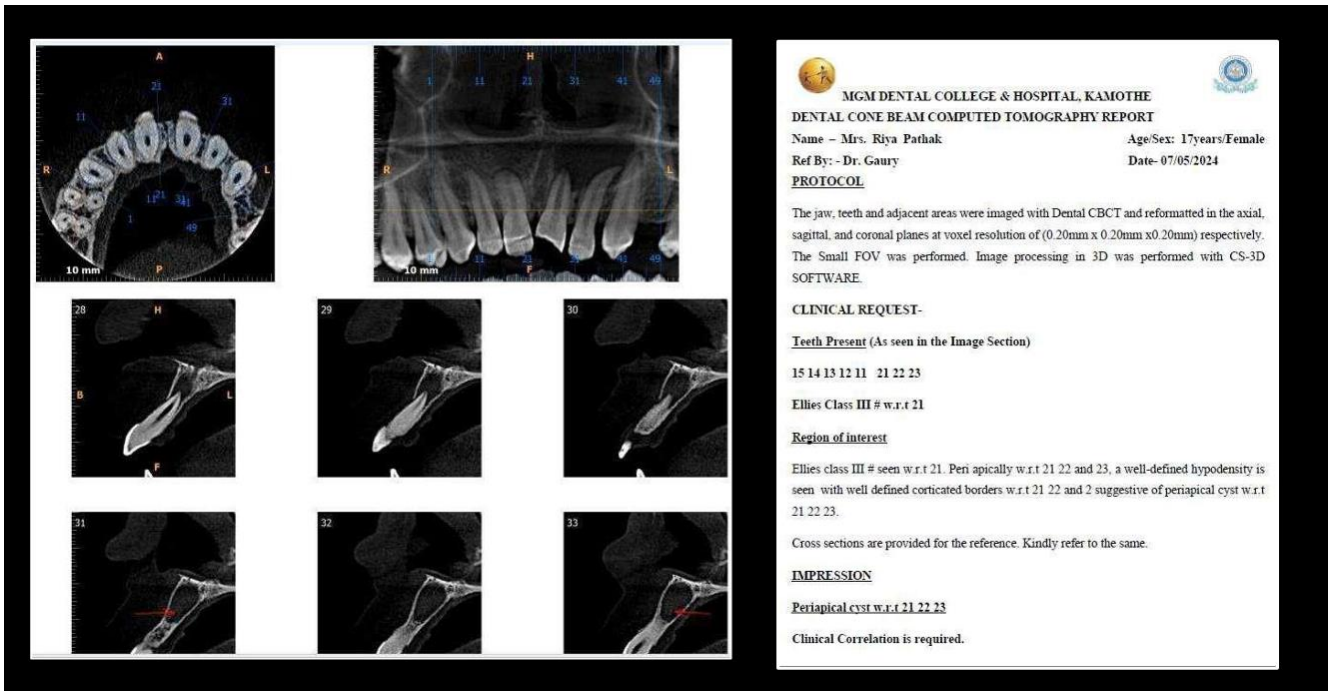


**Figure 3:** Cone Beam Computed Tomography (CBCT) images showing three-dimensional assessment of the lesion with corticated borders extending mesiodistally in relation to teeth 21, 22 and 23 with evident cortical plate expansion and periapical bone destruction

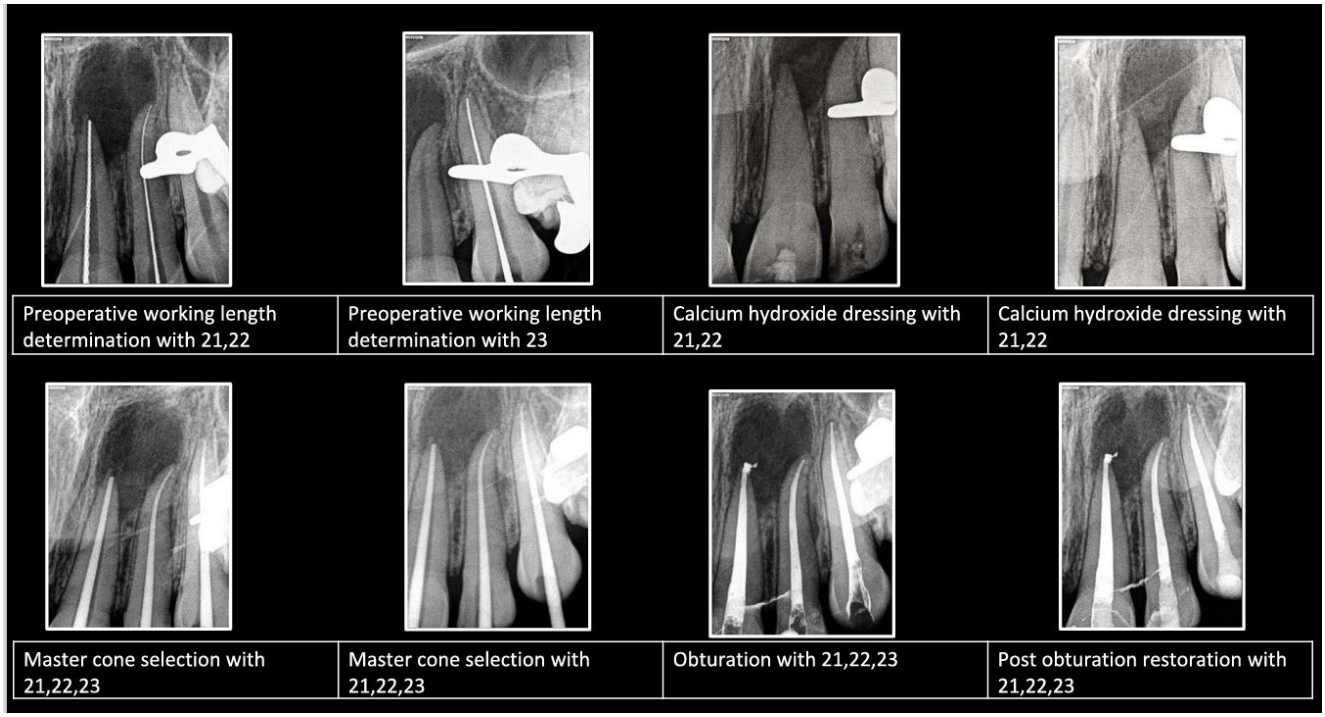


**Figure 4:** Intra-operative radiographic sequence showing working length determination, intracanal calcium hydroxide medicament placement, master cone selection and final obturation of teeth 21, 22 and 23 prior to surgical enucleation and apicectomy

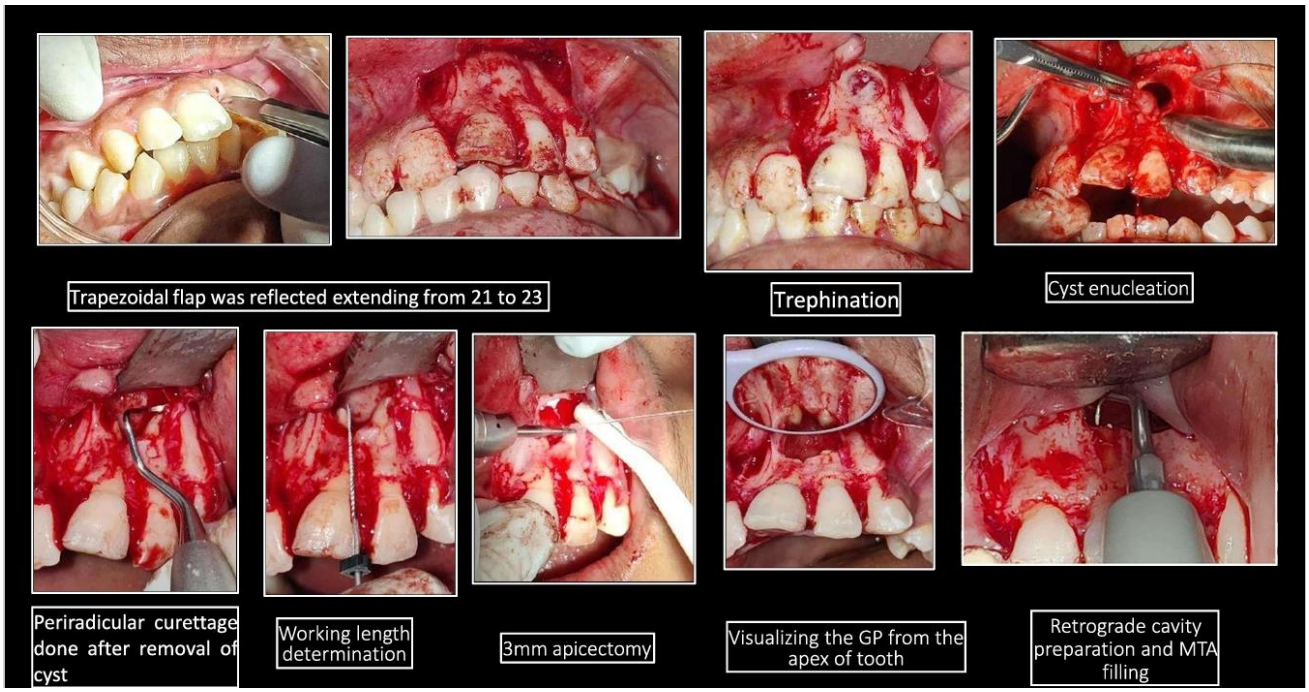


**Figure 5:** Intra-operative surgical management sequence demonstrating trapezoidal flap reflection, cortical trephination, cyst enucleation with periapical curettage, intra-operative working length determination, apicectomy, retrograde cavity preparation, placement of mineral trioxide aggregate (MTA) retrograde filling, and flap suturing

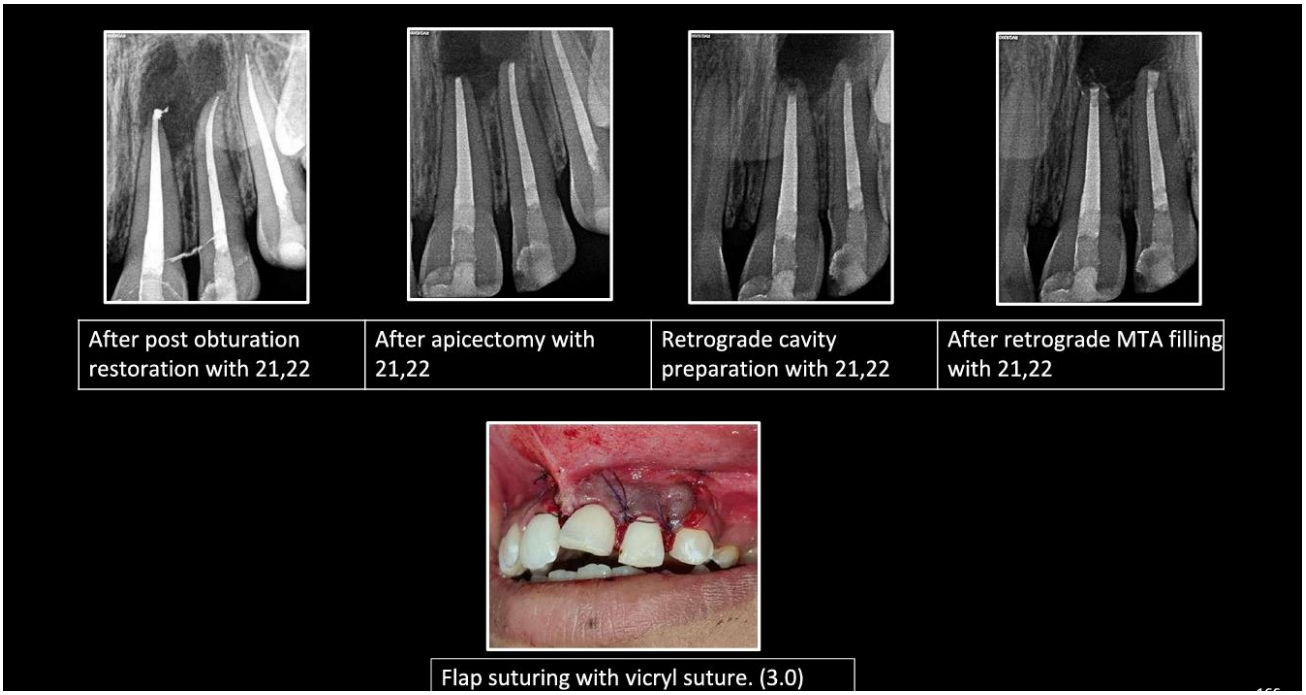


**Figure 6:** Sequential intra-oral periapical radiographs illustrating obturation, apical root resection, retrograde cavity preparation, and placement of retrograde MTA filling in relation to teeth 21 and 22

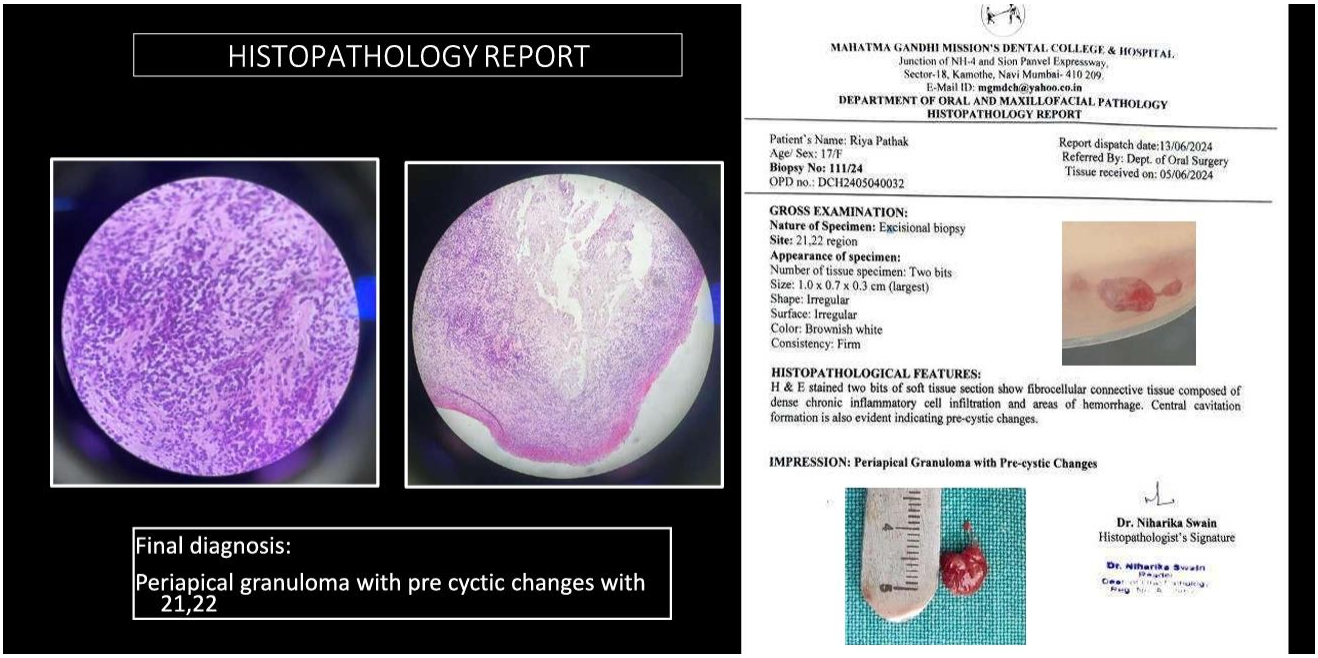


**Figure 7:** Gross specimen and histopathological evaluation of the excised lesion showing dense chronic inflammatory infiltrate within fibrocellular connective tissue consistent with periapical granuloma with pre-cystic changes

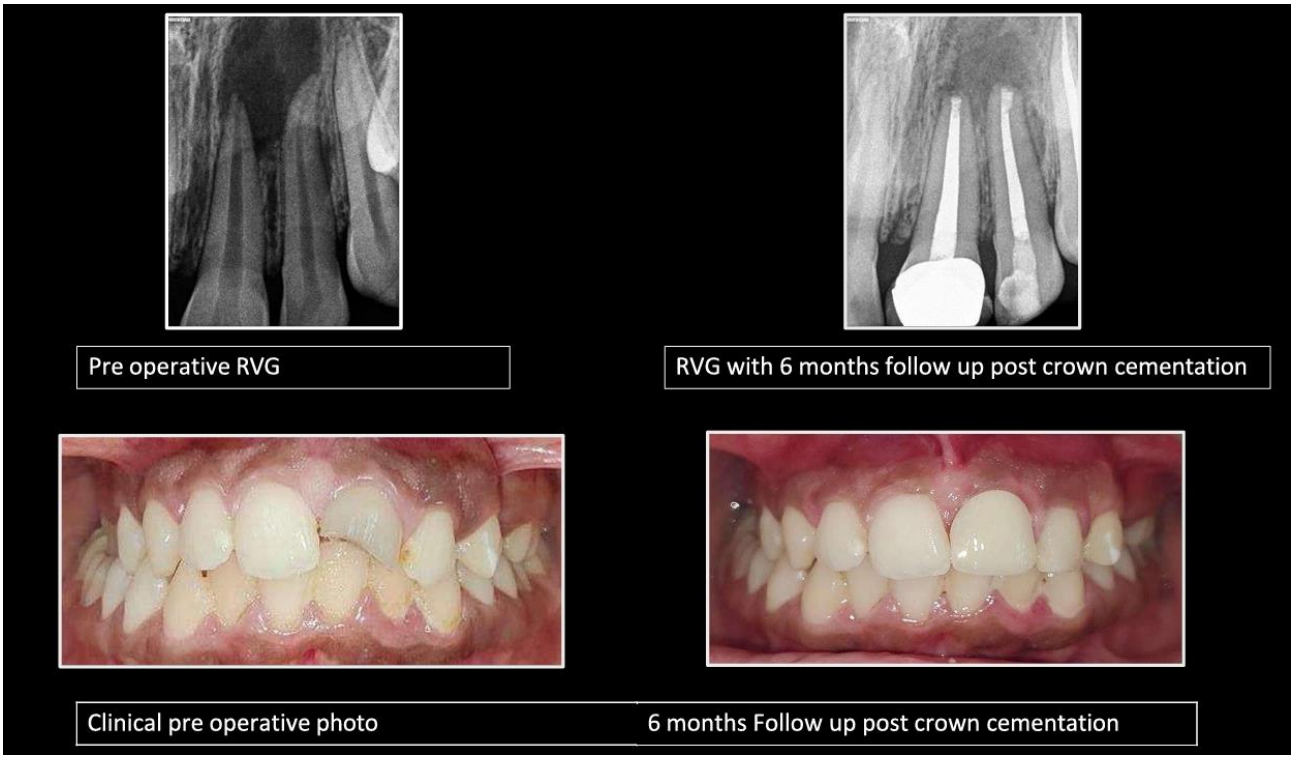


**Figure 8:** Preoperative clinical photograph and radiograph compared with 6-month postoperative follow-up images demonstrating satisfactory healing and functional and esthetic rehabilitation following crown placement.

## 3. Discussion

Large periapical lesions present diagnostic and therapeutic challenges owing to variations in biological behaviour and healing potential. These lesions develop following microbial ingress into the pulp space, resulting in necrosis and activation of host immune responses.[6,7] Although adequate root canal disinfection can promote healing in many cases, extensive lesions—particularly those demonstrating cystic transformation—may persist or resolve slowly after nonsurgical treatment.[8,9]

Dental trauma plays a major etiological role in pulpal necrosis affecting anterior teeth, especially in younger individuals.[2] The delayed manifestation of periapical pathology years after injury, as seen in the present case, has been widely documented. Radiographic evidence of well-circumscribed corticated radiolucencies often indicates chronic inflammatory lesions with potential cystic nature; however, definitive differentiation between granulomas and cysts cannot be established radiographically alone and requires histopathological examination.[10]

Intentional endodontic therapy of the adjacent vital tooth was undertaken considering the anticipated surgical exposure and possible compromise of pulpal vitality. Such preventive management has been advocated in cases where lesion proximity or surgical manipulation increases the likelihood of postoperative necrosis.[12]

Surgical enucleation facilitates thorough elimination of pathological tissues and immediate reduction of microbial burden. Apical root-end resection further enhances treatment success by removing apical ramifications, lateral canals, and delta systems that may harbour residual infection despite adequate orthograde preparation.[11] Removal of approximately 3 mm of the root apex has been reported to significantly decrease anatomical complexities and improve surgical prognosis.[12]

Mineral trioxide aggregate was selected as the retrograde filling material due to its favourable sealing properties, excellent biocompatibility, and ability to promote hard tissue formation.[13,14] Bioactive materials contribute to enhanced periapical healing by stimulating osteogenic and cementogenic responses.

The use of CBCT in preoperative assessment has revolutionised endodontic surgical planning by providing accurate three-dimensional visualization of lesion extent, cortical bone integrity, and proximity to structures such as the nasal floor and adjacent roots.[15,16] Such detailed imaging assists in minimizing intraoperative complications and improving clinical outcomes.

The favourable healing observed during follow-up in the present case underscores the effectiveness of an integrated nonsurgical and surgical approach. Adequate canal disinfection, meticulous surgical execution, complete lesion removal, and appropriate root-end sealing are critical determinants of successful management. Long-term monitoring remains essential to confirm sustained osseous regeneration and treatment stability.[17]

## 4. Clinical Significance

Large periapical lesions associated with traumatized anterior teeth can be successfully managed using a combined nonsurgical and surgical approach. Accurate CBCT-based diagnosis, me ticulous surgical technique, and use of bioactive retrograde materials are key factors in achieving predictable healing and long-term prognosis.

## List of Abbreviations

CBCT: Cone Beam Computed Tomography
IOPA: Intraoral Periapical Radiograph
MTA: Mineral Trioxide Aggregate
OPG: Orthopantomogram

## Author Contributions

**Manasi Surwade:** Conceptualization, case management, clinical investigation, surgical treatment, and manuscript drafting.
**Anuradha Patil:** Clinical supervision, treatment planning, and critical revision of the manuscript.
**Sumanthini M. V:** Radiographic assessment, literature review, data interpretation, and manuscript review.
**Divya Naik:** Histopathological evaluation, literature review, manuscript editing, and final approval of the manuscript. All authors reviewed and approved the final version of the manuscript.

## Declaration of Patient Consent

Written informed consent was obtained from the patient's parent/legal guardian for publication of this case report and accompanying clinical details and images.

## Financial Support and Sponsorship

None.

## Conflict of Interest

None.

## Use of Artificial Intelligence (AI)

The authors declare that no artificial intelligence (AI) tools were used in the generation, analysis, interpretation, or writing of this manuscript.

## Acknowledgment

The authors acknowledge the support of the Department of Conservative Dentistry and Endodontics for providing clinical guidance and facilities during the management of this case.

## References

1. Andreasen JO, Andreasen FM, Andersson L. *Textbook and Color Atlas of Traumatic Injuries to the Teeth*. 4th ed. Oxford: Blackwell Munksgaard; 2007.
2. Calişkan MK. Prognosis of large cyst-like periapical lesions following nonsurgical root canal treatment: a clinical review. *Int Endod J*. 2004;37(6):408–16. https://doi.org/10.1111/j.1365-2591.2004.00809.x
3. Estrela C, Bueno MR, Leles CR, Azevedo B, Azevedo JR. Accuracy of cone beam computed tomography and panoramic and periapical radiography for detection of apical periodontitis. *J Endod*. 2008;34(3):273–9. https://doi.org/10.1016/j.joen.2007.11.023
4. Kim S, Kratchman S. Modern endodontic surgery concepts and practice: a review. *J Endod*. 2006;32(7):601–23. https://doi.org/10.1016/j.joen.2005.12.010
5. Nair PN. New perspectives on radicular cysts: do they heal?. *Int Endod J*. 1998;31(3):155–60. https://doi.org/10.1046/j.1365-2591.1998.00146.x
6. Nair PN. Pathogenesis of apical periodontitis and the causes of endodontic failures. *Crit Rev Oral Biol Med*. 2004;15(6):348–81. https://doi.org/10.1177/154411130401500604
7. Parirokh M, Torabinejad M. Mineral trioxide aggregate: a comprehensive literature review--Part I: chemical, physical, and antibacterial properties. *J Endod*. 2010;36(1):16–27. https://doi.org/10.1016/j.joen.2009.09.006
8. Patel S, Dawood A, Ford TP, Whaites E. The potential applications of cone beam computed tomography in the management of endodontic problems. *Int Endod J*. 2007;40(10):818–30. https://doi.org/10.1111/j.1365-2591.2007.01299.x
9. Patel S, Durack C, Abella F, Shemesh H, Roig M, Lemberg K. Cone beam computed tomography in Endodontics - a review. *Int Endod J*. 2015;48(1):3–15. https://doi.org/10.1111/iej.12270
10. Ricucci D, Siqueira JF Jr. Biofilms and apical periodontitis: study of prevalence and association with clinical and histopathologic findings. *J Endod*. 2010;36(8):1277–88. https://doi.org/10.1016/j.joen.2010.04.007
11. von Arx T. Apical surgery: A review of current techniques and outcome. *Saudi Dent J*. 2011;23(1):9–15. https://doi.org/10.1016/j.sdentj.2010.10.004

12. Sjögren U, Figdor D, Persson S, Sundqvist G. Influence of infection at the time of root filling on the outcome of endodontic treatment of teeth with apical periodontitis. *Int Endod J.* 1997;30(5):297–306. https://doi.org/10.1046/j.1365-2591.1997.00092.x
13. Torabinejad M, Pitt Ford TR. Root end filling materials: a review. *Endod Dent Traumatol*. 1996;12(4):161–78. https://doi.org/10.1111/j.1600-9657.1996.tb00510.x
14. Tsesis I, Rosen E, Taschieri S, Telishevsky Strauss Y, Ceresoli V, Del Fabbro M. Outcomes of surgical endodontic treatment performed by a modern technique: an updated meta-analysis of the literature. *J Endod*. 2013;39(3):332–9. https://doi.org/10.1016/j.joen.2012.11.044
15. Scarfe WC, Levin MD, Gane D, Farman AG. Use of cone beam computed tomography in endodontics. *Int J Dent*. 2009;2009:634567. doi:10.1155/2009/634567
16. Simon JH. Incidence of periapical cysts in relation to the root canal. *J Endod*. 1980;6(11):845–8. https://doi.org/10.1016/S0099-2399(80)80039-2
17. Nair PN. Pathogenesis of apical periodontitis and the causes of endodontic failures. *Crit Rev Oral Biol Med*. 2004;15(6):348–81. https://doi.org/10.1177/154411130401500604