Journal of
Scientific Advances in Dentistry

REVO PUBLICATION

Case Report

Facial esthetic enhancement using cheek plumper with complete dentures: A case report

Gaurav Issar[1*], Shreya Jaiswal[1], Laxman P Rao[1], Pallavi Sirana[1], Ankita Pal[1], Mandeep Kaur[1]

[1]Department of Prosthodontics and Crown & Bridge, Institute of Dental Studies & Technologies, Modinagar, Uttar Pradesh, India

Abstract

Background: Complete denture rehabilitation should restore facial support, fulness as well as balanced occlusion, speech, and oral comfort. Loss of dentoalveolar support and reduced soft-tissue tone may appears deficient and low-profile cheeks, for which a cheek plumper can be used as an adjunct with complete as a supportive denture.

Case Presentation: An elderly female patient aged 57 years visited the Department of Prosthodontics, Institute of Dental Studies and Technologies Modinagar Ghaziabad with complaints regarding her existing complete dentures. The clinical examination showed completely edentulous maxillary and mandibles university with fully developed Atwood Order V ridges in the upper jaw and Order VI in the lower jaw, significantly lost cheek support as well as loss of facial fullness. Maxillary and mandibular complete dentures were constructed according to a conventional technique. Bilateral detatchable cheek plumper retained by a single stud attachment was incorporated in the maxillary denture which was evaluated for esthetics, phonetics, retention, stability comfort and ease of handling. The prosthesis remained well retained, stable, phonetics were acceptable, occlusion and facial contour were also satisfactory at follow-up. The patient was comfortable, well-handled and very satisfied with their improved facial appearance and overall prosthetic treatment.

Conclusion: A detachable stud-retained cheek plumper provided a simple, conservative, and adaptable approach for restoring lost cheek support. Its removable design facilitated independent cleaning and handling while maintaining satisfactory esthetics and denture functionand overall comfort.

Keywords: Complete denture, Cheek plumper, Detachable prosthesis, Precision attachment, Facial esthetics, Edentulous patient.

Received: 12-08-2026

Accepted: 18-09-2026

Published: 21-11-2026

***Corresponding author:** Gaurav Issar
Email: dr.issar@gmail.com

https://doi.org/10.65929/JSAD.2026.1.3.008

How to cite this article: Issar G, Jaiswal S, Rao LP, Sirana P, Pal A, Kaur M. Facial esthetic enhancement using cheek plumper with complete dentures: A case report. *J Sci Adv Dent*. 2026;1(3):131-136.

© 2026 The Author(s). Published by REVO Publication.

This is an Open Access article distributed under the terms of the Creative Commons Attribution 4.0 International License (CC BY 4.0) (https://creativecommons.org/licenses/by/4.0/), which permits unrestricted use, distribution, and reproduction in any medium, provided the original work is properly cited.

1. Introduction

Facial esthetics is an essential part of the treatment of complete denture. While the denture base and artificial teeth make up part of lost dentoalveolar volume, conventional contours may not restore knee support to cheeks provided by natural teeth in conjunction with underlying alveolar ridges and associated soft tissues.[1,2] As a result, cheek bones may remain hollowed or sunken after tooth loss and this may suggest to the patient that they are older and less socially confident.[2,3]

A cheek plumper is an adjunctive prosthetic device designed to support missing cheek structures, also known as a cheek-lifting appliance. It either can be incorporated into the denture as a single non-removable element or manufactured separately and retained with magnets, press-button systems, pins, ball attachments, hooks, orthodontic buttons or custom components.[3]

Non-detachable designs are uncomplicated, but may tend to bulking and heavy maxillary denture which makes insertion and removal more difficult and might also impair retention or muscle comfort. A component that supports the facial-plumper profile is designed to be detachable from the denture, thus allowing its easy insertion, removal and cleaning, while permitting the use of a denture with or without the plumper when clinically indicated.[3]

This is a Case Report of a planned rehabilitation in a 55-year-old female patient with complete dentures reinforced with an attachment-retained detachable cheek plumper. This report focuses on case evaluation, prosthesis design, clinical procedures, patient instructions and documentation of results.

2. Case Presentation

2.1. Patient information

A 57-year-old female patient with completely edentulous maxillary and mandibular arches reported to the Department of Prosthodontics, at Institute of Dental Studies and Technologies, Modinagar, Ghaziabad, with dissatisfaction regarding her existing complete dentures. The patient had been wearing complete dentures for the past 5 years but was not satisfied with the esthetics and facial appearance provided by her previous prosthesis and desired a different prosthetic design.

On intraoral examination, completely edentulous maxillary and mandibular arches were observed (**Figure 1**). The maxillary residual ridge was broad, rounded and moderately resorbed, corresponding to Order V of Atwood's classification, whereas the mandibular residual ridge exhibited marked resorption with a low, flattened configuration, corresponding to Order VI of Atwood's classification. The overlying mucosa appeared clinically healthy and intact.

Extraoral examination revealed loss of facial fullness and inadequate cheek support, contributing to a relatively sunken appearance of the cheeks and reduced facial esthetics. Considering the patient's dissatisfaction with her previous dentures and her primary concern regarding inadequate cheek support, a treatment plan was formulated to rehabilitate the patient with maxillary and mandibular complete dentures incorporating a detachable cheek plumper in the maxillary denture.

The detachable cheek plumper was planned to restore lost cheek fullness and improve facial esthetics while providing the advantages of easy removal, maintenance and adjustment, thereby offering greater versatility and patient acceptance.

2.2. Clinical examination and diagnosis

Extraoral examination was performed both at rest and also during smiling, speaking and functional movements. The clinician assessed cheek hollowing, lip support, and lower facial height bilaterally at rest and with smiles; noted facial midline; and recorded the patient preferred contour of their face. Clinical examination comprised intraoral evaluation of the edentulous ridges, mucosa, vestibular anatomy, interarch space, position of the tongue, conditions of saliva and presence of an area that could impede the path of insertion or movement against buccinator and masseter muscles.

The patient was diagnosed as totally edentulous maxillary and mandibular arches. The goals of treatment were to re-establish adequate facial contour, provide retained and well-tolerated complete dentures prostheses, maintain speech and oral function, allow for self-sufficiency in handling and hygiene whilst preventing oversized or overly heavy prosthesis. (**Figure 1**, **Figure 2**)

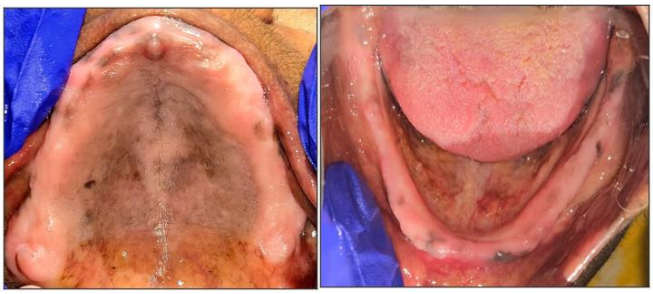

Figure 1: Pre-treatment intraoral pictures.



Figure 2: Pre-treatment extraoral pictures

3. Treatment Plan

The definitive design included maxillary complete denture (s) with a [bilateral] removable cheek plumper.

Press stud attachment was chosen as the attachment system and denture-side component fixed in distobuccal flange area of denture base. The design was evaluated for sufficient interarch and buccal space, a reproducible path of insertion, passive fit, resistance to rotation, retrievability and cleanability.

4. Clinical Procedure

4.1. Preliminary procedures

Impression compound was used to record primary impressions for maxillary and mandibular arches. Type II gypsum was poured for the diagnostic casts. Self-cure resin was used to fabricate custom trays, and border molding was performed using low fusing green stick compound. Direct impressions with zinc oxide eugenol paste were made.

Records were made of the vertical dimension, centric relation, occlusal plane Lip support, phonetics and smile display. personalised artificial teeth were carefully arranged according to the facial decided upon by Ito et al Following this, the width and colour of these files were chosen according to the patient's age, sex and esthetic preferences. (**Figure 3**)

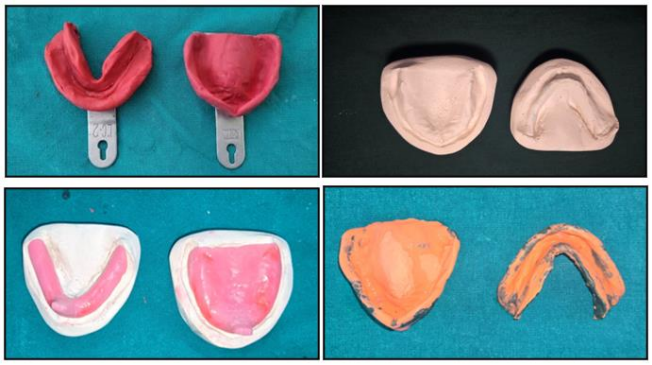

Figure 3: Primary and final Impressions and diagnostic casts

4.2. Design and trial evaluation of the cheek plumper

At the wax try-in stage, the cheek plumper contour was achieved over bilateral buccal area of the denture during management. The contour was gradually sculpted, with the patient being evaluated at rest, during smiling and speech. The plumper was away from the teeth, occlusal contacts, functional vestibular movements and muscle attachments. The last contour, however, was adopted because it improved facial support without an overfilled or unnatural look. (**Figure 4**)



Figure 4: Wax try-in and evaluation of facial support

4.3. Processing and attachment incorporation

After performing trial setup, denture and plumper were made from heat-polymerized acrylic resin. Weight was observed, the laboratory processing in setting attachment on the denture-side and plumper-side is done.

The attachment was installed to seat the plumper completely, reliably. The finishing and polishing included the intaglio surface, borders, and the attachment housing. The prosthesis was examined for sharp edges, porosity, tissue impingement, attachment interference and occlusal changes. Retention, stability, palatal fit (which provides facial support), phonetics and esthetics were evaluated extraorally, and patient comfort was verified intraorally. (**Figure 5**)



Figure 5: Definitive prosthesis and attachment components

4.4. Insertion and patient instructions

Maxillary and mandibular complete dentures were inserted, then the detachable cheek plumper was intraorally attached to the maxillary denture. The patient was educated about how to orient the plumper and that positioning is crucial, as well as was trained on inserting and removing it without force. Instructions were also given for appropriate cleaning of the full denture and detachable cheek plumper.

The patient received instructions to remove the prosthesis at night, perform proper oral and prosthesis hygiene, and inspect the oral mucosa for irritation or soreness on a regular basis. She was trained to review in case of liberal, slack, brokenness, misfortune of retention, or trouble in putting or pulling out the cheek plumper.

The insertion appointment revealed that the prosthesis was retained and stable, phonetics and occlusion were acceptable, and also improved facial contour with better support of the cheeks. Comfort and ease of handling of the detachable cheek plumper were well accommodated by the patient, and he reported high satisfaction with the overall esthetic and functional outcome.

Uniform follow-up visits were programmed at 24–48 hours, 1 week and as then as necessary to monitor the prosthesis, current position of oral tissues, retention of attachment and satisfaction from patient. (**Figure 6**)



Figure 6: Pre and post-insertion appearance with the detachable cheek plumper

5. Discussion

Loss of teeth and progressive resorption of the residual alveolar ridges can result in to collapse of the cheeks and a change in the outline of an ageing lower third of face. Traditional complete dentures restore oral structures as well but may not provide support for the overlying facial tissues in patients with severely resorbed ridges. In such cases, the addition of a cheek plumper is used to enhance the buccal silhouette and recover the facial volume.[4]

In the current case, a single stud attachment incorporated in the maxillary complete denture was utilized to retain an attachable cheek plumper. The retention of the plumper was retained by means of an attachment but it was removable from the denture. The detachable configuration permitted the separate cleaning of the device and enhanced patient handling. This design was especially convenient for this patient because the necessary cheek support from acrylic could be supplied to the denture base without permanently adding extra acrylic bulk.[1]

The cheek plumper has to be placed well so that the natural facial contour is restored. Both the quantity and position of buccal addition must be evaluated in clinical and laboratory phases to give appropriate support yet minimize over-contouring or an unnatural appearance. The plumper has to also match with the determined contours of the dentures and movements associated with functional interacting parts in the mouth.[6]

The design with an attachment retained requires more room in the denture to house the components of the attachment and this may not always be able to be achieved without compromising the strength or contour of the prosthesis. Proper placement of attachment also plays an important role in ensuring adequate retention between the denture and detachable portion. Variants, including attachment-retained cheek plumpers tailored to patient needs have been reported thus, illustrating that attachment-based designs can be modified for different prosthetic requirements.[7]

Another consideration on the fabrication of cheek plumpers is how to reduce unnecessary bulk. Hollow and modified designs have been associated with reduced additional weight from the increased acrylic volume while still following the desired facial contour. Prosthesis weight control is particularly important in patients with severely resorbed ridges to ensure that proper denture retention and stability can be obtained.[8]

The clinical improvement in facial fullness of the present case is consistent with the previously reported applications of cheek plumpers among subjects bearing oral prosthesis. Proper buccal contour restorative plays a key role in enhancing facial aesthetics and improving the patient experience for overall prosthetic appearance.[9]

The positive results of the present case with respect to retention, stability, phonetics and comfort, along with ease of handling further endorses the clinical relevance of a detachable cheek plumper retained by stud attachment.[10]

Latest descriptions of customized attachment-retained cheek plumpers reiterate the importance of individualized attachment positioning and design while achieving adequate retention with acceptable prosthodontic contours.[11] The current method adheres to that idea, with the stud affixed acting as a localized mechanical means of retaining the removable portion in

customizing the facial support while permitting modification independent of denture base.

Esthetics with complete dentures goes beyond the restoration of missing dentition, it also involves restoring facial support. Objective methods to evaluate changes in facial soft-tissue morphology following complete denture treatment have shown that prosthetic rehabilitation affects the entire face.[12]

In the present case, the addition of the cheek plumper provided supplementary support to the buccal tissues and contributed to improvement in facial fullness, which was reflected in the patient's subjective satisfaction.

4.1. Clinical significance

In completely edentulous patients with inadequate cheek support and loss of facial contour caused by a satisfactory complete denture, an attachment-retained cheek plumper may be considered. The removable connection enables an enhancement of the buccal profile and allows the added part to be extracted separately without bonding with the denture. A defined example of when this method would be useful could include reconstructed facial tissues that require additional prosthetic bulk to restore volume but would undesirably interfere with denture handling, comfort or functional performance.[1,9]

Appropriate patient selection and prosthetic planning determine clinical success. Dentures that have a stable foundation, with sufficient space to include the attachment and positioned perfectly are crucial for denture retention and stability. Utilizing a predictable method of insertion and removal supports consistent involvement of the deployable element, while careful shaping of the plumper allows for proper facial rest without excessive projection or functional compromise.[6,7]

Clinical applicability of this technique is also patient factor dependant chloroethane. Manual dexterity and comprehension; a detachable element requires inserting, removing, and caring for coherently. By individualizing the plumper according to the severity of cheek deficiency and facial morphology, it is possible to tailor the degree of support provided to patient needs.[8,9] Accordingly, a removable stud-retained cheek plumper is considered a viable adjunct to complete denture therapy for appropriate patients in whom restoration of facial volume is an important aspect of the prosthetic treatment goal.

6. Conclusion

This case report presents a conservative approach to enhance lip support for an edentulous female aged 55 years during fabrication of complete dentures. A removable cheek plumper held in place via a proprietary retention system may provide cheek contour restoration with the ability to independently remove and clean.

Abbreviations

CD: Complete Denture
CP: Cheek Plumper

Author Contributions

Gaurav Issar: Conceptualization, case management, clinical supervision, and manuscript preparation.
Shreya Jaiswal: Clinical assistance, data collection, and manuscript drafting.
Laxman P Rao: Clinical assistance, literature review, and critical revision of the manuscript.
Pallavi Sirana: Literature review, data collection, and manuscript editing.
Ankita Pal: Clinical documentation, data organization, and manuscript editing.
Mandeep Kaur: Supervision, manuscript review, and final approval of the manuscript.

All authors reviewed and approved the final version of the manuscript and agree to be accountable for all aspects of the work.

Declaration of Patient Consent

Written informed consent was obtained from the patient for publication of this case report and clinical photographs.

Financial Support and Sponsorship

None.

Conflict of Interest

The authors declare no conflicts of interest.

Use of Artificial Intelligence (AI)

The authors declare that no artificial intelligence (AI) tools were used in the generation, analysis, interpretation, or writing of this manuscript.

References

1. Martone AL. Effects of complete dentures on facial esthetics. *J Prosthet Dent.* 1964;14:231–55. https://doi.org/10.1016/0022-3913(64)90084-8
2. Bains JW, Elia JP. The role of facial skeletal augmentation and dental restoration in facial rejuvenation. *Aesthetic Plast Surg.* 1994;18(3):243–6. https://doi.org/10.1007/BF00449788

3. Keni NN, Aras MA, Chitre V. Customised attachments retained cheek plumper prosthesis: a case report. *J Indian Prosthodont Soc.* 2012;12(3):198–200. https://doi.org/10.1007/s13191-012-0132-y
4. Deogade SC. Magnet retained cheek plumper in complete denture esthetics: a case report. *J Dent (Tehran).* 2014;11(1):100–5.
5. Kamakshi V, Anehosur GV, Nadiger RK. Magnet retained cheek plumper to enhance denture esthetics: case reports. *J Indian Prosthodont Soc.* 2013;13(3):378–81. https://doi.org/10.1007/s13191-012-0200-3
6. Shah RJ, Chaturvedi AT, Prajapati HG, Malek FG, Darji BJ, Katyayan PA. Enhancement of patient aesthetics using detachable cheek plumpers in complete dentures: case series. *Sch J Med Case Rep.* 2014;2(9):615–7. https://doi.org/10.36347/sjmcr.2014.v02i09.012
7. Vande AV, Kore A, Sanyal P, Nilesh K. Customized attachment retained hollow cheek plumper to enhance esthetics in elderly: report of a novel technique. *Int J Contemp Med Res*. 2019;6(6). https://doi.org/10.21276/ijcmr.2019.6.6.58
8. Pudi S, Kota S, Ch KVG, Kaladi SR, Gade RR. An innovative technique using a stainless steel double die pin retained cheek plumper in complete denture esthetics: a case report. *Cureus.* 2019;11(11):e6197. https://doi.org/10.7759/cureus.6197.
9. Raju R, Alani MM, Francis G, Reba PB. A technique to improve complete denture esthetics using cheek plumpers: a case report. *IOSR J Dent Med Sci*. 2020;19(2):52–4. https://doi.org/10.9790/0853-1902155254
10. Gagnier JJ, Kienle G, Altman DG, Moher D, Sox H, Riley D; CARE Group. The CARE guidelines: consensus-based clinical case reporting guideline development. *Headache*. 2013;53(10):1541–7. https://doi.org/10.1111/head.12246
11. Bhushan P, Aras MA, Coutinho I, Rajagopal P, Mysore AR, Kumar S. Customized cheek plumper with friction lock attachment for a completely edentulous patient to enhance esthetics: a clinical report. *J Prosthodont.* 2019;28(1):e1–e5. https://doi.org/10.1111/jopr.12591
12. Pucciarelli MGR, Toyoshima GHL, Neppelenbroek KH, Sforza C, de Menezes M, Oliveira TM, et al. Evaluation of labial protrusion and lip esthetic changes after complete denture treatment through stereophotogrammetry. *Int J Prosthodont*. 2024;37(6):615–24. https://doi.org/10.11607/ijp.8623