Journal of
Scientific Advances in Dentistry

REVO PUBLICATION

Case Report

Adhesive rehabilitation of a structurally compromised endodontically treated molar with a lithium disilicate veneerlay: One-year follow-up

Amira Yousfi[1*], Zohra Nouira[1], Belhassen Harzallah[1], Jilani Saafi[1]

[1]Dept. of Prosthodontics, Faculty of Dental Medicine of Monastir, Tunisha

Abstract

The restoration of structurally compromised endodontically treated posterior teeth requires careful assessment of the remaining tooth structure and appropriate selection of restorative strategies. This case report describes the adhesive rehabilitation of a structurally compromised endodontically treated mandibular second molar using a lithium disilicate veneerlay without intraradicular post placement, with clinical and radiographic evaluation at one-year follow-up. A 30-year-old male patient presented with recurrent fracture of a previous restoration on tooth 47, extensive coronal destruction, and inadequate root canal obturation. Endodontic retreatment was performed using rotary instruments, followed by coronal build-up with bulk-fill composite. The remaining lingual cusps and peripheral tooth structure were preserved to support an adhesive partial-coverage restoration. A lithium disilicate veneerlay was digitally designed, milled, and adhesively cemented. At one-year follow-up, clinical examination revealed satisfactory marginal integrity, stable occlusion, healthy periodontal tissues, and no evidence of secondary caries, restoration debonding, or fracture. Periapical radiography showed no evidence of new periapical pathology. A lithium disilicate veneerlay without intraradicular post placement may represent a conservative restorative option for appropriately selected endodontically treated posterior teeth with sufficient residual coronal and peripheral tooth structure to support adhesive rehabilitation. Long-term clinical studies are required to further evaluate the durability and predictability of this approach.

Keywords: Adhesive rehabilitation, Lithium disilicate, Veneerlay, Partial-coverage restoration.

Received: 08-08-2026
Accepted: 12-10-2026
Published: 21-11-2026

***Corresponding author:** Amira Yousfi
Email: amirayoussfi1@gmail.com

https://doi.org/10.65929/JSAD.2026.1.3.006

How to cite this article: Yousfi A, Nouira Z, Harzallah B, Saafi J. Adhesive rehabilitation of a structurally compromised endodontically treated molar with a lithium disilicate veneerlay: One-year follow-up. *J Sci Adv Dent.* 2026;1(3):116-122.

© 2026 The Author(s). Published by REVO Publication.

This is an Open Access article distributed under the terms of the Creative Commons Attribution 4.0 International License (CC BY 4.0) (https://creativecommons.org/licenses/by/4.0/), which permits unrestricted use, distribution, and reproduction in any medium, provided the original work is properly cited.

1. Introduction

Restoring a posterior tooth with extensive loss of tooth structure is often difficult, particularly after endodontic treatment. The choice of restoration should be based on the amount and condition of the remaining tooth structure, its distribution, and the quality of the endodontic treatment, as these factors influence the prognosis of the restored tooth.[1]

The remaining tooth structure also plays a role in deciding whether a post is necessary. Although posts may be indicated when insufficient tooth structure is available to provide adequate core retention, their use should be determined according to the specific restorative requirements. Unnecessary post-space preparation requires additional removal of radicular dentin and may compromise the structural integrity of the root.[2]

Advances in adhesive dentistry and restorative ceramics have expanded the indications for conservative rehabilitation of extensively damaged posterior teeth. Partial-coverage restorations, including onlays, overlays,

and adhesive partial crowns, can provide cuspal protection while limiting the removal of sound enamel and dentin compared with conventional full-coverage preparations.[3] Among the available ceramic materials, lithium disilicate is particularly suitable for posterior adhesive restorations because of its favorable mechanical and optical properties and its predictable bonding potential following appropriate surface conditioning.[4,5]

These characteristics can be effectively exploited in partial-coverage designs such as the veneerlay, which combines occlusal coverage with extension onto selected axial surfaces while maintaining a conservative preparation design.[6] This approach may be particularly advantageous when substantial tissue loss requires cuspal coverage while sufficient peripheral tooth structure remains available for adhesive bonding.[7]

The present report describes the adhesive rehabilitation of a structurally compromised endodontically treated mandibular second molar using a bulk-fill flow composite core and a lithium disilicate veneerlay without intraradicular post placement, with clinical and radiographic evaluation at one-year follow-up.

2. Case Presentation

A 30-year-old male patient was referred to the Department of Prosthodontics for rehabilitation of the mandibular right second molar (tooth 47). His medical history was non-contributory. The patient reported recurrent fracture of a previous restoration associated with difficulty during mastication (**Figure 1**a). Clinical examination revealed extensive coronal destruction secondary to recurrent caries, with complete loss of the buccal cusps. Periodontal examination showed no increased probing depths or tooth mobility, and occlusal analysis revealed stable intercuspal contacts without evidence of traumatic occlusion. Periapical radiographic examination demonstrated inadequate previous root canal obturation, with voids within the root filling (**Figure 1b**). Following failure of the previous restoration, the root canal filling had remained exposed to saliva for several months. Despite the extensive coronal destruction, the tooth was considered restorable based on the presence of preserved lingual cusps and peripheral tooth structure, which provided a favorable substrate for adhesive reconstruction. Because of the inadequate root canal obturation and prolonged salivary contamination, endodontic retreatment was performed before definitive prosthetic rehabilitation.



Figure 1: Initial clinical and radiographic assessment of tooth 47. **(a):** Extensive coronal destruction with loss of the buccal cusps. **(b):** Inadequate previous root canal treatment with voids in the root filling

The existing gutta-percha was removed under rubber dam isolation using Rogin Dental retreatment rotary files (Shenzhen Rogin Medical Co., Ltd, China). Working length was established using an electronic apex locator (Woodpex V, Woodpecker Medical Instrument Co., Ltd., China) and confirmed radiographically. Canal preparation was completed using E-Flex Blue rotary instruments (Eighteeth Medical Technology, Jiangsu, China) to a final apical preparation size of 25/.06 for the mesial canals and 30/.06 for the distal canal, according to the canal anatomy. Irrigation was performed throughout instrumentation using 2.5% sodium hypochlorite, followed by a final irrigation sequence with 17% ethylenediaminetetraacetic acid (EDTA) and sterile saline. Manual dynamic agitation was performed using a well-fitting master gutta-percha cone. The canals were subsequently obturated with gutta-percha cones and B&E Root-Sil sealer (B&E KOREA Co., Ltd., Republic of Korea) using the single-cone technique (**Figure 2**). A postoperative periapical radiograph confirmed satisfactory obturation (**Figure 3**a).

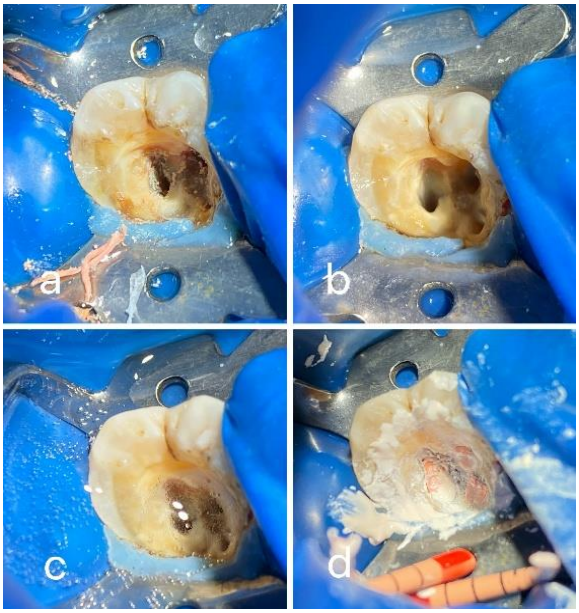

Figure 2: Endodontic retreatment of tooth 47**. (a)** Gutta-percha removal. **(b)** Canal cleaning and shaping. **(c)** Sodium hypochlorite activation. **(d)** Root canal obturation

Following endodontic retreatment, restorative rehabilitation was initiated. The remaining lingual cusps were uniformly reduced by approximately 2 mm to provide adequate space for the definitive ceramic restoration while preserving the maximum amount of sound tooth structure. Residual gutta-percha extending into the pulp chamber and carious tissue were removed under the guidance of a caries detector dye (**Figure 3**b, c). A universal adhesive system (All-Bond Universal; BISCO Inc., Schaumburg, IL, USA) was applied according to the manufacturer's instructions, and the coronal build-up was completed using B&E Bulk Flow composite (B&E KOREA Co., Ltd., Republic of Korea), placed in increments not exceeding 4 mm and light-cured according to the manufacturer's recommendations (**Figure 3**d, e).

The tooth was subsequently prepared to receive a lithium disilicate veneerlay restoration. Occlusal reduction was performed using an occluso-shaper diamond bur to provide approximately 2 mm of occlusal clearance, followed by preparation of a buccal chamfer finish line using a 1.2-mm-diameter chamfer diamond bur (**Figure 4**a). Sharp external line angles were rounded to minimize stress concentration within the ceramic restoration, and the preparation was subsequently finished using TOR VM polishing discs to obtain smooth, well-defined preparation surfaces. Following completion of the preparation, a double-cord gingival retraction technique was performed to achieve adequate gingival displacement and expose the preparation margin before the final impression (**Figure 4**b). A single-step polyvinyl siloxane impression was then obtained using I-Sil Premium (Spident, Republic of Korea) (**Figure 4**c), followed by recording of the maxillomandibular relationship using BMS VinylBite registration material (BMS Dental, Italy) (**Figure 4**d).

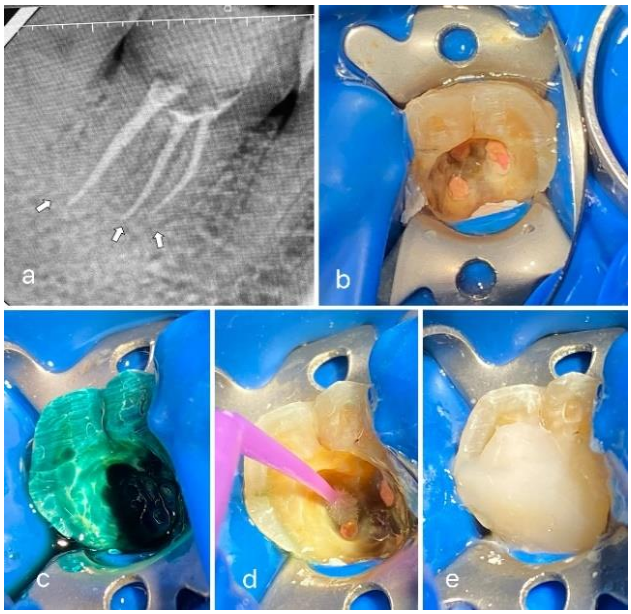

Figure 3: Endodontic and restorative procedures. **(a)** Postoperative radiograph after obturation. **(b)** Removal of residual gutta-percha. **(c)** Caries removal using caries detector dye. **(d)** Adhesive application. **(e)** Core build-up



Figure 4: Tooth preparation and impression. **(a)**: Tooth preparation. **(b):** Double-cord gingival retraction. **(c)**: Final polyvinyl siloxane impression. **(d)**: Bite registration

The veneerlay was designed with exocad software (exocad GmbH, Darmstadt, Germany) and milled from lithium disilicate glass ceramic (IPS e.max CAD; Ivoclar, Schaan, Liechtenstein) (**Figure 5**). The restoration was first tried intraorally to check its marginal adaptation, proximal contacts, and seating. Once a satisfactory fit was confirmed, rubber dam isolation was achieved, and the veneerlay was tried in again to verify its complete seating under isolation (**Figure 6**a).

The enamel was etched with 37% phosphoric acid for 10 seconds, followed by etching of the remaining preparation for a further 5 seconds, providing a total etching time of 15 seconds for enamel and 5 seconds for dentin. The tooth was then thoroughly rinsed, and excess water was removed while avoiding desiccation of the dentin. All-Bond Universal adhesive (BISCO Inc., Schaumburg, IL, USA) was applied, gently air-thinned, and light-cured for 10 seconds (**Figure 6**b, c).

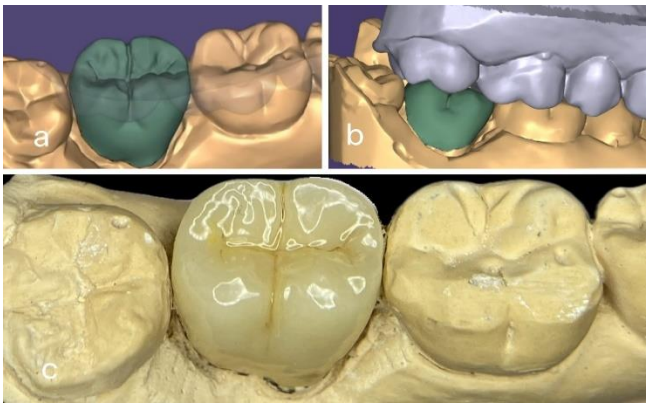

Figure 5: CAD/CAM fabrication of the lithium disilicate veneerlay. **(a):** Digital design. **(b):** Milled veneerlay restoration

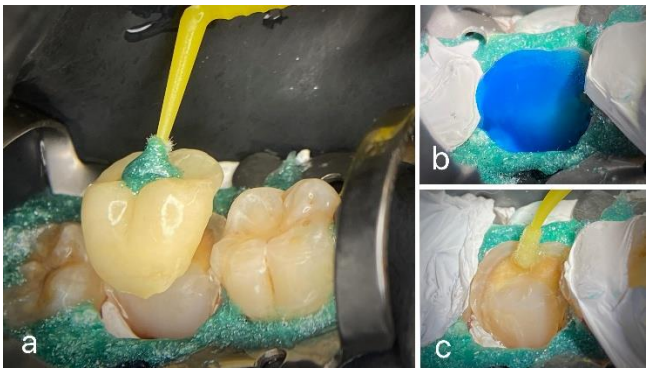

Figure 6: Veneerlay try-in and tooth surface conditioning. **(a):** Try-in under rubber dam isolation. **(b)**: Enamel and dentin etching. **(c):** Adhesive application.

The intaglio surface of the lithium disilicate veneerlay was treated with 9% hydrofluoric acid for 20 seconds, thoroughly rinsed, and subsequently cleaned with 37% phosphoric acid to remove insoluble reaction residues formed during ceramic etching. A pre-hydrolyzed silane coupling agent (BISCO Silane; BISCO Inc., Schaumburg, IL, USA) was then applied according to the manufacturer's instructions. A dual-cure adhesive resin cement (Duo-Link Universal Resin Luting Cement; BISCO Inc., Schaumburg, IL, USA) was applied to the treated intaglio surface of the veneerlay (**Figure 7**).



Figure 7: Surface treatment of the lithium disilicate veneerlay before adhesive cementation

The restoration was carefully seated onto the prepared tooth, and excess resin cement was removed from the margins. Each accessible surface was light-cured for 40 seconds, after which the margins were carefully inspected to ensure complete removal of excess cement. Occlusion was verified in maximum intercuspation and during excursive movements. At the two-week follow-up appointment, the patient reported mild occlusal discomfort. Occlusal contacts were reassessed, and minor adjustments were performed where necessary, followed by polishing with the DIAPOL Twist polishing system (EVE Ernst Vetter GmbH, Pforzheim, Germany) (**Figure 8**a,b).



Figure 8: Veneerlay cementation and two-week follow-up. **(a):** Seating of the lithium disilicate veneerlay and removal of excess resin cement; **(b):** Finishing and polishing following occlusal adjustment at the two-week follow-up

At the one-year follow-up examination, the patient was asymptomatic and reported satisfactory functional performance. Clinical evaluation demonstrated

satisfactory marginal integrity, stable occlusion, healthy periodontal tissues, and no evidence of secondary caries, restoration debonding, or fracture. Periapical radiographic examination showed maintained periapical health, with no evidence of new periapical pathology (**Figure 9**a, b).

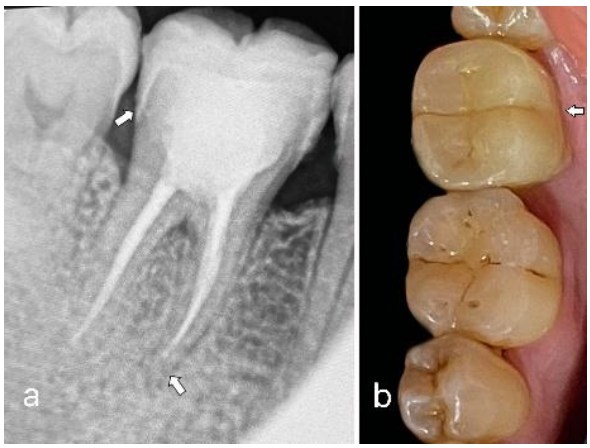

Figure 9: One-year clinical and radiographic evaluation of tooth 47. **(a):** Periapical radiographic evaluation; **(b):** Occlusal clinical view.

3. Discussion

The present case describes the adhesive rehabilitation of a structurally compromised endodontically treated molar using a lithium disilicate veneerlay without post placement. Three key clinical decisions shaped the treatment approach: the selective avoidance of intraradicular posts, the choice of a partial-coverage veneerlay design, and the adhesive bonding protocol employed.

The decision to omit an intraradicular post was based on the quantity and distribution of the remaining coronal tooth structure rather than on a categorical avoidance of post placement. Despite complete loss of the buccal cusps, the preserved lingual cusps and peripheral enamel and dentin provided a favorable substrate for adhesive reconstruction. Consequently, the remaining coronal structure was considered sufficient to support the planned bonded partial-coverage restoration without additional radicular intervention.[1,1] This selective approach is supported by Fersrari Cagidiaco et al., who reported no statistically significant effect of post placement on the survival of lithium disilicate partial crowns in teeth with at least 50% of coronal structure remaining.[9]

A second major decision concerned the restorative design. Following coronal build-up with a bulk-fill resin composite, the definitive restoration was designed as a lithium disilicate veneerlay rather than a conventional full-coverage crown. The rationale for selecting a partial-coverage design is supported by biological and biomechanical considerations. Recent evidence has shown that conventional complete-crown preparations require substantially greater removal of sound tooth structure than more conservative preparation designs.[3] The compression-dome concept also highlights the importance of preserving the enamel-dentin complex from a biomechanical perspective.[10] In the present case, the preparation was therefore designed to provide adequate cuspal coverage while avoiding unnecessary removal of sound peripheral tooth structure.

Lithium disilicate was selected to complement this conservative restorative approach. In addition to its favorable mechanical and optical properties, its glassy microstructure allows hydrofluoric acid etching. Recent experimental studies have shown that minimally invasive CAD/CAM lithium disilicate partial-coverage restorations can perform well under fatigue loading when compared with single crowns, supporting the use of more conservative partial-coverage designs.[5] Clinical findings are consistent with this biomechanical rationale. Prott et al. reported a 3-year survival rate of 93.7% for lithium disilicate posterior partial-coverage restorations,[3] while Malament et al. documented favorable long-term outcomes over a follow-up period of approximately 17 years.[11] Similar results have been reported by Lane et al. and Alhamdan et al., who found favorable clinical outcomes with cuspal-coverage and adhesively bonded partial restorations in endodontically treated posterior teeth.[12,13]

The ceramic-resin interface is another key consideration in this type of restoration. In the present case, the lithium disilicate surface was conditioned with hydrofluoric acid and silane before cementation. This treatment combines micromechanical retention with chemical interaction between the ceramic surface and the resin cement, and has been widely used for bonding lithium disilicate and other glass ceramics.[14,15]

The tooth surface was treated with a universal adhesive containing functional monomers. Among these, 10-MDP can interact with hydroxyapatite and form a relatively stable chemical bond.[16] The formation of MDP nanolayers at the interface has also been proposed as one of the factors contributing to the stability and strength of the adhesive bond.[17] In clinical practice, however, the quality of this interface is not determined by the adhesive alone. Isolation, preservation of sound tooth structure, preparation design, ceramic surface treatment, and the cementation procedure all have a role in achieving a reliable bond.[18,19]

After one year, the restoration was still functioning well, with no clinical symptoms and a satisfactory radiographic appearance. This result is in agreement with previous reports on adhesive partial-coverage restorations made with lithium disilicate.[3] However, the follow-up in the present case is relatively short, and the observation of only one patient does not allow conclusions about the long-term behavior of the restoration. The absence of a control or comparison group is another limitation.

The treatment also required good isolation and careful adhesive procedures. Since the remaining tooth structure was already compromised, preserving the sound tissues and avoiding unnecessary removal during preparation were particularly important. In this case, the combination of conservative preparation and adhesive cementation provided a satisfactory result at the one-year recall.[18,19]

4. Conclusion

A conservative approach is preferable when rehabilitating structurally compromised endodontically treated posterior teeth. Preserving the remaining tooth structure and maintaining a suitable adhesive substrate are central to this approach. In selected cases, an adhesively bonded lithium disilicate veneerlay can provide cuspal protection without extensive removal of sound dental tissues. Careful evaluation of the residual tooth structure is required before treatment. The preparation and restorative design must also be appropriate, and the adhesive procedures should be performed carefully. Further long-term clinical studies are necessary to assess the longevity of this minimally invasive approach and its applicability to a broader range of cases.

List of Abbreviations

1. CAD: Computer-Aided Design
2. CAM: Computer-Aided Manufacturing
3. EDTA: Ethylenediaminetetraacetic Acid
4. MDP: 10-Methacryloyloxydecyl Dihydrogen Phosphate

Author Contributions

Amira Yousfi: Conceptualization, clinical investigation, patient management, and manuscript drafting.
Zohra Nouira: Clinical supervision and critical revision of the manuscript.
Belhassen Harzallah: Clinical guidance, interpretation of clinical findings, and manuscript review.
Jilani Saafi: Supervision, validation, and final approval of the manuscript. All authors reviewed and approved the final version of the manuscript.

Declaration of Patient Consent

Written informed consent was obtained from the patient for publication of this case report and clinical photographs.

Financial Support and Sponsorship

None.

Conflict of Interest

The authors declare no conflicts of interest.

Use of Artificial Intelligence (AI)

The authors declare that no artificial intelligence (AI) tools were used in the generation, analysis, interpretation, or writing of this manuscript.

References

1. Ferrari M, Pontoriero DIK, Ferrari Cagidiaco E, Carboncini F. Restorative difficulty evaluation system of endodontically treated teeth. *J Esthet Restor Dent Off Publ Am Acad Esthet Dent Al.* 2022;34(1):65–80. https://doi.org/10.1111/jerd.12880
2. Naumann M, Schmitter M, Frankenberger R, Krastl G. "Ferrule Comes First. Post Is Second!" Fake News and Alternative Facts? A Systematic Review. *J Endod*. 2018;44(2):212–9. https://doi.org/10.1016/j.joen.2017.09.020
3. Prott LS, Pieralli S, Klein P, Spitznagel FA, Ibrahim F, Metzendorf MI, et al. Survival and Complications of Partial Coverage Restorations on Posterior Teeth-A Systematic Review and Meta-Analysis. *J Esthet Restor Dent Off Publ Am Acad Esthet Dent Al.* 2025;37(3):620–41. https://doi.org/10.1111/jerd.13353
4. Spitznagel FA, Boldt J, Gierthmuehlen PC. CAD/CAM Ceramic Restorative Materials for Natural Teeth. *J Dent Res.* 2018;97(10):1082–91. https://doi.org/10.1177/0022034518779759
5. Spitznagel FA, Prott LS, Hoppe JS, Manitckaia T, Blatz MB, Zhang Y, et al. Minimally invasive CAD/CAM lithium disilicate partial-coverage restorations show superior in-vitro fatigue performance than single crowns. *J Esthet Restor Dent Off Publ Am Acad Esthet Dent Al*. 2024;36(1):94–106. https://doi.org/10.1111/jerd.13169
6. Ferraris F. Posterior indirect adhesive restorations (PIAR): preparation designs and adhesthetics clinical protocol. Int J Esthet Dent. 2017;12(4):482–502.
7. Fichera G, Mazzitelli C, Picciariello V, Maravic T, Josic U, Mazzoni A, et al. Structurally compromised teeth. Part I: Clinical considerations and novel classification proposal. *J Esthet Restor Dent Off Publ Am Acad Esthet Dent Al*. 2024;36(1):7–19. https://doi.org/10.1111/jerd.13117

8. Carvalho MA de, Lazari PC, Gresnigt M, Del Bel Cury AA, Magne P. Current options concerning the endodontically-treated teeth restoration with the adhesive approach. *Braz Oral Res*. 2018;32(suppl 1):e74. https://doi.org/10.1590/1807-3107bor-2018.vol32.0074
9. Ferrari Cagidiaco E, Verniani G, Pontoriero DIK, Saracutu OI, Manfredini D, Ferrari M. Posterior partial crowns out of lithium disilicate with or without posts: A randomized controlled study at 9 years follow up. *J Dent*. 2025;161:106005. https://doi.org/10.1016/j.jdent.2025.106005
10. Milicich G. The compression dome concept: the restorative implications. *Gen Dent.* 2017;65(5):55–60.
11. Malament KA, Margvelashvili-Malament M, Natto ZS, Thompson V, Rekow D, Att W. Comparison of 16.9-year survival of pressed acid etched e.max lithium disilicate glass-ceramic complete and partial coverage restorations in posterior teeth: Performance and outcomes as a function of tooth position, age, sex, and thickness of ceramic material. *J Prosthet Dent.* 2021;126(4):533–45. https://doi.org/10.1016/j.prosdent.2020.08.013
12. Lane J, Sadeghzadeh-Araghi A, Jackson G, Bonsor S. Survival and Success Rates of Endodontically Treated Teeth Restored with Full Veneer Crowns or Full Cuspal Coverage onlays: A Systematic Review. *Eur J Prosthodont Restor Dent.* 2024;32(1):45–55. https://doi.org/10.1922/EJPRD_2547Lane11
13. Alhamdan MM, Alghuwainem N, Alharbi M, Hummady S. Clinical Outcome of Indirect Bonded Porcelain Restoration Versus Full-Coverage Crown on Endodontically Treated Teeth in Posterior Areas: A Systematic Review. Cureus. 2024 Sep;16(9):e70116. https://doi.org/10.7759/cureus.70116
14. Porto TS, Faddoul AJ, Park SJ, Feitosa VP, Eyüboğlu TF, Ozcan M. Optimal Hydrofluoric Acid Etching Duration and Impact of Silane/Adhesive on Profilometric Properties and Bonding to Lithium Disilicate Glass Ceramics. *Oper Dent*. 2024;49(5):617–26. https://doi.org/10.2341/24-015-L
15. Kanzow P, Lechte C, Wiegand A, Grandini S, Malvicini G, Marruganti C, et al. Bond strength of resin composite to glass-based, oxide, and polymer-infiltrated ceramics after different surface pretreatment methods: Systematic review and network meta-analysis. *J Dent.* 2025;162:106051. https://doi.org/10.1016/j.jdent.2025.106051
16. Yoshida Y, Nagakane K, Fukuda R, Nakayama Y, Okazaki M, Shintani H, et al. Comparative study on adhesive performance of functional monomers. *J Dent Res*. 2004;83(6):454–8. https://doi.org/10.1177/154405910408300604
17. Yoshihara K, Nagaoka N, Nakamura A, Hara T, Yoshida Y, Van Meerbeek B. Nano-Layering Adds Strength to the Adhesive Interface. *J Dent Res.* 2021;100(5):515–21. https://doi.org/10.1177/0022034520979133
18. Cardoso JA, Almeida PJ, Negrão R, Oliveira JV, Venuti P, Taveira T, et al. Clinical guidelines for posterior restorations based on Coverage, Adhesion, Resistance, Esthetics, and Subgingival management. The CARES concept: Part I – partial adhesive restorations. *Int J Esthet Dent.* 2023;18(3):244–65.
19. Ghodsi S, Shekarian M, Aghamohseni MM, Rasaeipour S, Arzani S. Resin cement selection for different types of fixed partial coverage restorations: A narrative systematic review. *Clin Exp Dent Res.* 2023;9(6):1096–111. https://doi.org/10.1002/cre2.761